



PATIENT

Chester Vincze

SPECIES

Feline

BREED

DLH

SEX

Male Neutered

AGE

11 years

WEIGHT

9.36lbs

INTERPRETED BY

Maggie Machen
Lamy, DVM
DACVIM (Cardiology)

PRESENTING CLINICAL SIGNS

History: Chester is referred to evaluate a heart murmur. He was diagnosed with hyperthyroidism in June 2022. Last TT4 was high end of normal at 3.6 (high normal 4.0). He is scheduled for I 131 treatment and needs a pre-treatment echo and blood pressure. Good appetite; normal activity level. Isolated episode of open mouth breathing over a month ago. On exam: NSR, grade IV/VI parasternal murmur, PSS, lung fields clear, compressible thorax. BP: 140mmHg x 5. Current medications: Felimazole/methimazole 2.5mg 1.5 tabs twice a day *No sedation for study.

ECHOCARDIOGRAM FINDINGS

2D, m-mode, color flow and Doppler imaging is available.

Left ventricle: The LV diameter is normal with adequate myocardial function. The LV wall thicknesses are normal. There is a diffusely hyperechoic endocardium consistent with mild fibrosis. The endocardium appears mildly remodeled. The papillary muscles are mildly remodeled and hyperechoic.

Left atrium: The left atrium is mildly increased in size. No obvious spontaneous contrast or thrombi seen.

Mitral valve: The mitral valve is normal in structure and mobility. No obvious systolic anterior motion is seen.

Aortic valve/aorta: The aortic valve is normal in morphology and mobility. Normal aortic outflow velocity; laminar flow. No aortic insufficiency.

Right ventricle: Normal right ventricular diameter and morphology indicating no overt evidence of pulmonary arterial hypertension.

Right atrium: The right atrium is normal in dimension.

Tricuspid valve: The tricuspid valve appears normal with no tricuspid regurgitation.

Pulmonic valve/pulmonary artery: The pulmonic valve is normal in morphology and mobility. No pulmonic insufficiency. Normal RVOT velocity; laminar flow.

Pericardium/other: No pericardial or pleural effusion noted. No obvious cardiac masses.

Heart rhythm: ECG reveals a sinus rhythm with an average HR of 188bpm.

IMAGING

PERFORMED BY

Pamela Harrigan,
RDCS

HOSPITAL NAME

Mass Veterinary
Services

REFERRING VET

Dr. Masloski

INVOICE

27132

DATE

10/26/22

2-Dimensional Measurements

Ao diam (cm)	1.0
LA diam (cm)	1.5
LA:Ao (Swe)	1.5
IVS thickness (cm)	0.51
LVID diastole (cm)	1.67
PW thickness (cm)	0.48
LVID systole (cm)	0.7
FS (%)	58

Doppler Measurements

PV Vmax (m/s)	1.0
AoV Vmax (m/s)	1.5
MR Vmax (m/s)	NA
TR Vmax (m/s)	NA
TR PG (mmHg)	NA

INTERPRETATION OF THE FINDINGS

The only abnormality identified is mild left atrial enlargement. In the absence of significant LV pathology, this may reflect early Unclassified cardiomyopathy. A normal variant is not ruled out. This can also be caused by uncontrolled hyperthyroidism; however, given the timeframe this is considered unlikely. Regardless, no additional issues are identified. No cause for the murmur is identified in this study, making it likely physiologic in origin (i.e., secondary to tachycardia, volume changes, etc.).



PATIENT
Chester Vincze

With mild abnormalities seen here, no medications are clearly indicated. Whether this is a clear contraindication for I 131 therapy could be debated. The safest option would be to treat orally for 6 months and screen for any progressive changes prior to proceeding. Discussion with the owner is advised.

SPECIES
Feline

Prognosis is guarded prior to assessing for progression.

BREED
DLH

RECOMMENDATIONS

- Given these findings, no medications are indicated.
- The risk for general anesthesia is low, however heart rate stimulating drugs such as atropine, glycopyrrolate, etc. should be avoided unless medically necessary. With mild LA dilation there may be an elevated risk for fluid overload in this patient and judicious IV fluid use is recommended.
- Monitor for any clinical evidence of cardiac compromise, including respiratory changes and/or signs of a blood clot event (paralysis, neurologic changes, etc.)

SEX
Male Neutered

AGE

11 years

PLAN

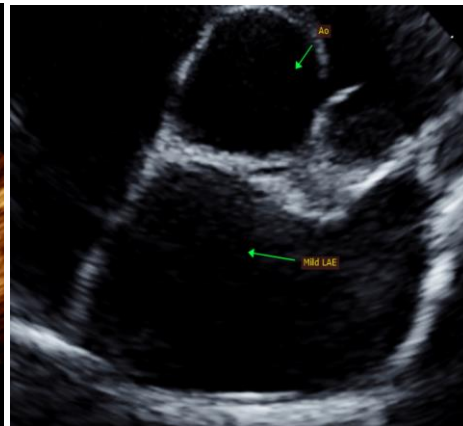
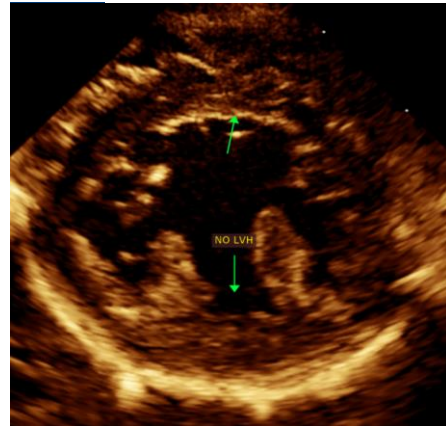
- Recommend recheck echocardiogram in 6-12 months to reassess murmur origin and screen for progressive LA dilation.

WEIGHT
9.36lbs

IMAGES

INTERPRETED BY

Maggie Machen
Lamy, DVM
DACVIM (Cardiology)



IMAGING PERFORMED BY

Pamela Harrigan,
RDCS

HOSPITAL NAME

Mass Veterinary Services

The information and recommendations provided are based on the images presented by the referring veterinarian. No evaluation can be communicated regarding pathology that was not visible in the image/video clips provided.

REFERRING VET

Dr. Masloski

Thank you for this referral. This report was generated using transcription software, and minor dictation errors may be present. If the clinical or image interpretation does not parallel your findings or if I can be of any further assistance, please contact me.

INVOICE

27132

Maggie Machen Lamy, DVM

Diplomate of the American College of Veterinary Internal Medicine (Cardiology)
info@sonopath.com

DATE

10/26/22

Echocardiogram performed by:

Pamela Harrigan, RDCS
Pet Animal Ultrasound Service (4paus.com)